International Journal of Pediatric Otorhinolaryngology 76 (2012) 1355–1360

Contents lists available at SciVerse ScienceDirect

International Journal of Pediatric Otorhinolaryngology

journal homepage: www.elsevier.com/locate/ijporl

# Functional endoscopic sinus surgery (FESS) alone versus balloon catheter sinuplasty (BCS) and ethmoidectomy: A comparative outcome analysis in pediatric chronic rhinosinusitis☆

Prasad John Thottam [a,b,c,d,*], Michael Haupert [a,b,d], Sonal Saraiya [a,b,d], James Dworkin [a,d], Ranga Sirigiri [a,b,d], Walter M. Belenky [a,b,d]

[a] Detroit Medical Center, United States
[b] The Children's Hospital of Michigan, United States
[c] Michigan State University, United States
[d] Wayne State University, Detroit, MI, United States

ARTICLE INFO

*Article history:*
Received 24 March 2012
Received in revised form 11 June 2012
Accepted 15 June 2012
Available online 6 July 2012

*Keywords:*
Pediatric
Balloon sinuplasty
Balloon catheter sinuplasty
BCS
Sinusitis
Sinus disease
Sinus surgery
Chronic sinusitis
Chronic rhinosinusitis
Pediatric chronic rhinosinusitis
FESS
Functional endoscopic sinus surgery

ABSTRACT

*Objective:* To evaluate whether the addition of BCS (balloon catheter sinuplasty) would improve the treatment outcome in children with chronic rhinosinusitis (CRS) compared to FESS (functional endoscopic sinus surgery).
*Study design:* Two-group, retrospective cohort with blinded chart review comparison.
*Setting:* Children's Hospital of Michigan, Detroit, MI.
*Subjects and methods:* Chart review of 15 pediatric patients who underwent BCS with ethmoidectomy and 16 who underwent FESS from 2008 to 2011 for treatment of CRS in a tertiary care, university affiliated, pediatric institution. Pre-operative CT-scans as well as pre and post-operative sinus symptoms and medications were compared. Post-surgical outcome was examined using chi square analysis.
*Results:* Mean age of children at the time of the procedure was 9.3 (SD = 4.19; range = 3–17). Both groups had similar pre-surgical Lund–Mackay CT CRS scores (FESS: mean = 9.33 and $t = 0.67$; balloon: mean = 10.58, $t = 0.68$, and $p = 0.51$). Analyses identified significant post-treatment reductions in overall symptoms and needed interventions in both treatment groups. Side-by-side post-operative comparison of patients who underwent balloon sinuplasty to FESS demonstrated statistically significant post-operative difference between the two groups in antibiotic requirement, sinus congestion and headaches. Though not statistically significant, 62.5% of FESS patients and 80.0% of BCS patients ($\chi^2 = 1.15$) reported improvement in their overall sinus symptoms post-operatively.
*Conclusion:* Both BCS and FESS are suitable treatments for CRS in children. Both treatments significantly reduced CRS complaints post-operatively and had similar overall results. BCS patients required significantly fewer antibiotics post-operatively for CRS related disease when compared to FESS. Larger prospective studies with long-term data are needed to further evaluate.


## 1. Introduction

Chronic rhinosinusitis (CRS) is a common disease afflicting both adults and children. Approximately 15% of the population in the United States suffer from this condition, and more than five billion dollars per year is spent treating this disease [1]. For children with CRS refractory to medical treatment, conventional functional endoscopic sinus surgery (FESS) is an effective treatment, but associated morbidities, complications and results are variable. There has been recent inquiry regarding whether the addition of balloon catheter sinuplasty (BCS) techniques would significantly improve the treatment outcome in children who undergo surgery for CRS [2]. Preliminary reports suggest that when FESS is combined with balloon dilation, initial symptoms of facial pain, sinus congestion, post-nasal-drip, rhinorrhea and headaches are substantially less severe [3]. This treatment outcome has not been extensively corroborated in the scientific literature. Moreover, there is a paucity of research investigation comparing combined BCS + ethmoidectomy versus FESS alone, relative to overall treatment outcomes in a cohort pediatric sample population.

☆ Research results were presented as an oral presentation on September 13, 2011 in the Rhinology section at AAO-HNS Annual Meeting in San Francisco, CA.

* Corresponding author at: Department of Pediatric Otolaryngology, Children's Hospital of Michigan, 3901 Beaubien Street, Detroit, MI 48201, United States. Tel.: +1 330 936 6915; fax: +1 313 745 5848.
*E-mail address:* pthottam@gmail.com (P.J. Thottam).

0165-5876/$ – see front matter © 2012 Elsevier Ireland Ltd. All rights reserved.
http://dx.doi.org/10.1016/j.ijporl.2012.06.006

The paranasal sinuses (frontal, ethmoid, maxillary and sphenoid) are mucosa-lined compartments that are physically contiguous with the nasal cavity [4]. The exact function of the paranasal sinuses is unknown, but it has been theorized that they assist in moistening and humidifying ambient air, act as resonant chambers for voice, and serve to dampen and protect the brain from trauma [4]. The anatomical continuity of the sinuses with the nasal cavity, nasopharynx, and middle ear space helps explain the propensity of bacterial and viral spread to and from these interconnected structures [5]. CRS due to infectious processes or gross anatomical abnormalities adversely affects normal drainage and cavity aeration [6].

The FESS procedure works by physically removing, altering and opening sinus air cells or drainage pathways to create greater continuity, mucous flow and sinus aeration. For this study, traditional FESS will be used to describe total ethmoidectomy together with maxillary antrostomy with uncinectomy and/or frontal sinusotomy. Theoretically, BCS is a less traumatic procedure that works directly on the natural openings of the various sinuses. This technique involves the placement of a balloon tipped catheter into the openings of the sinus followed by balloon inflation. The natural ostia are radially widened as a consequence. At our institution, BCS is used to treat the maxillary and frontal sinus ostia in combination with traditional FESS ethmoidectomy.

Whereas FESS and BCS have each been separately investigated in children with intractable CRS, the efficacy of combining the two techniques for synergistic treatment effects and individual comparative outcomes has not been extensively studied [1,3,7]. Both FESS and BCS have shown to be more effective then adenoidectomy, and other known treatments for pediatric CRS [1,7,8]. Furthermore, when compared to FESS, BCS has been shown to result in fewer complications in both children and adults with CRS (0.01% per patient) [3,9].

The current investigation was designed to examine otherwise healthy children who were treated for CRS with FESS alone or BCS with ethmoidectomy. Improvements in core presenting sinus symptoms of facial pain, post-nasal-drip, rhinorrhea, headaches and sinus congestion were examined in detail. These specific symptoms, along with other complaints, have been described in the Otolaryngology Head & Neck Surgery 2007 clinical guidelines on adult sinusitis and have been used for the development of SN-5 (Sinus and Nasal quality of life survey) and SNOT-21 (Sino-Nasal Outcome Test) quality of life questionnaires [10–12]. Use of antibiotics and topical nasal steroids prior to, and following surgery was also investigated for comparative purposes, as were overall complication factors and rates associated with each surgical approach. We hypothesized that children who underwent combined BCS and ethmoidectomy would experience similar outcomes relative to sinus symptoms, medication requirements, and complications post-operatively to those who submitted to FESS alone.

## 2. Methods and materials

### 2.1. Subjects

The charts of 106 patients (ages 3–17) with the diagnosis of CRS and who underwent sinus surgery were reviewed from the clinical database within the department of pediatric otolaryngology at The Children's Hospital of Michigan from 2008 to 2011. From this database, children diagnosed with craniofacial abnormalities, immunodeficiency disorders, or mucociliary diseases were excluded from this study. Furthermore, any child with complicated rhinosinusitis as described by the 2007 Sinusitis guidelines, with sino-nasal polyps or unilateral sinus disease were excluded [10]. In order to maintain the goal of examining these two different sinus surgery techniques, children who underwent intra-operative sinus irrigations and/or combined FESS and BCS treatments directed at the maxillary or frontal sinuses were excluded as well.

From this pool, 31 children in whom CRS persisted despite standard maximal medical therapy met the inclusion criteria for this investigation [5]. All subjects had no other documented medical conditions, besides complaints of seasonal allergies. These children had two or more symptoms related to sinus disease preoperatively despite trials of nasal steroids, nasal saline, oral antihistamines, decongestants, oral antibiotic and sometimes IV antibiotic therapy. These individuals experienced intractable symptoms for at least 90 days. 13 children (8 BCS; 5 FESS) did undergo adenoidectomy at a previous date for obstructive sleep apnea ± rhinitis symptoms, but were still having persistent CRS complaints. For these specific children, traditional FESS or BCS with ethmoidectomy were employed, with no patients receiving adenoidectomy at the time of surgery. Each subject had to have completed at least pre-surgical, and final post-surgical examinations.

### 2.2. Measures

Charts were examined for various demographic data points including age and gender. Charts were also assessed for CRS diagnosis with minimal improvement despite standard maximal medical therapy, history of previous sinus surgery. Patient's charts were examined for reports of cough, headache, rhinorrhea, facial pain, postnasal drip, and/or congestion refractory to medical therapy and affecting daily life. All sinus symptoms and medical therapy were assessed pre-, 2–4 weeks post- and final post-surgical exam (>4 months, average of 37 weeks). CT evidence of paranasal sinus disease was obtained and a Lund–Mackay score was completed for each subject pre-operatively.

#### 2.2.1. Surgical outcomes

A total symptom score was constructed (1 point for each symptom if reported as being present for at least 6 h a day and affecting daily life and no points if symptom did not affect daily life or was absent) for the number of complaints pre-surgery, post-surgery, and at the final post-surgical exam for the following: facial pain, sinus congestion, post nasal drip, rhinorrhea, headache, and low-grade fever. Success and improvement were defined as a decrease in the total complaint score of 1 or more points at last visit. While total improvement was defined as total resolution of all complaints (i.e., symptom score of 0).

All data were obtained from clinic charts and operating room records of patients cared for by four board certified pediatric otolaryngologists and three pediatric radiologists. Charts reviewed were randomly assigned a number regardless of treatment process. Each chart was appraised for history of sinus complaints, clinical and laboratory examinations conducted, treatments rendered both pharmacologically and surgically, and outcomes obtained. Data for each subject were independently coded on a standardized record form by two separate blinded otolaryngologists to control for inter-rater reliability level of agreement. In the final analysis, inter rater reliability for the entire study population was 90%. No patients of the above mentioned coding physicians' were used in this study to control for bias.

### 2.3. Design and data analysis

The investigation employed a two-group, retrospective cohort, blinded chart review methodology. Descriptive statistics including frequency distributions, measures of central tendency (mean, median, and mode), and dispersion were conducted on all study variables. To examine pre-surgical differences between groups, independent *t*-tests and chi square analyses were employed. To

**Table 1**
Patient characteristics, symptoms (averages and total individual number) and medication use by surgical group pre-operatively.

| | Mean, number or % | | $t$ or $\chi^2$ | $p$ |
|---|---|---|---|---|
| | FESS | Balloon | | |
| Child age | 9.1 | 9.5 | −0.20 | 0.89 |
| Gender (% male) | 62.5 | 60.0 | 0.00 | 0.96 |
| Adenoidectomy (% yes) | 31.3 | 53.3 | 1.55 | 0.21 |
| Lund–Mackay total score | 9.3 | 11.5 | −1.26 | 0.22 |
| Total symptoms (avg.) | 2.8 | 2.5 | 0.64 | 0.52 |
| Facial pain (total) | 7 | 7 | 0.00 | 1.00 |
| Sinus congestion (total) | 8 | 11 | 1.17 | 0.28 |
| Post nasal drip (total) | 9 | 9 | 0.00 | 1.00 |
| Rhinorrhea (total) | 10 | 13 | 1.39 | 0.24 |
| Headaches (total) | 10 | 7 | 1.13 | 0.29 |
| Low grade fever (total) | 2 | 0 | 2.00 | 0.16 |
| Antibiotics (total) | 0.9 | 1.5 | −0.55 | 0.16 |
| Allergy medications (total) | 0.8 | 1.1 | −0.61 | 0.01 |
| Nasal steroid spray (total) | 0.6 | 0.7 | −2.25 | 0.44 |

examine potential differences between left and right sinuses' (frontal and maxillary) Lund–Mackay scores across surgical groups paired-$t$-tests were performed. To examine the potential differences in surgical outcomes, one-tailed chi square analyses were used. For chi-square analysis examining the impact of a surgical procedure on an outcome, a one-tailed analysis was used due to our a priori hypothesis that balloon patient outcome post-surgery would show similar improvement to those patients undergoing traditional FESS.

In addition, to ensure there were no differences between surgical groups prior to surgical procedure, logistic regression analysis was performed to identify differences in frontal and maxillary sinus disease between groups. A MANOVA (Multivariate Analysis of Variance) was performed to identify the impact of age, gender, and previous adenoidectomy on total symptom scores at pre-, post- and final post surgical exam.

Protocol summary was reviewed by the Detroit Medical Center, Michigan State University and Wayne State University Institutional Review Board (IRB), Wayne State University Human Investigation Committee and granted full approval for the collection and reporting of data in this study. Protocol #: 1004008242/HIC#046710MP4E.

## 3. Results

### 3.1. Sample

The mean age for a child identified with CRS was 9.3 (SD = 4.19; range = 3–17); 61.3% were male. Of these 31 participants, 16 (51.6%) were treated with traditional FESS and 15 (48.4%) underwent traditional ethmoidectomy with balloon sinuplasty. The average total Lund–Mackay score was 10.4 (SD = 4.8). Mean differences between the left sinus and right sinus frontal and maxillary Lund–Mackay scores across all patients were not significant. Independent $t$-test assessing pre-surgical Lund–Mackay scores between BCS and FESS subjects found no significant difference (FESS: mean = 9.33; balloon: mean = 11.53, $t = -1.26$). Table 1 demonstrates no statistically significant difference between the two groups pre-operatively besides allergy medication use.

As demonstrated in Fig. 1, a total of 84 maxillary and/or frontal sinuses were addressed surgically along with ethmoidectomy (BCS = 40; FESS = 44). Among patients who underwent bilateral BCS, 30 maxillary sinuses and 10 frontal sinuses were dilated. On the other hand, 32 maxillary and 12 frontal sinuses were addressed using bilateral traditional maxillary antrostomy with uncinectomy and Draf I/IIA frontal sinusotomy techniques. Certain patients did not receive surgery addressing their frontal sinuses either due to the absence of disease on imaging or anatomical development.

### 3.2. BCS and FESS treatment results

BCS with ethmoidectomy and traditional FESS exhibited post-treatment improvements in all examination categories except use of nasal steroids. Table 2 illustrates the overall decrease in reports of a specific pre-operative complaint at final post-surgical visit. Such improvements were defined as reports of a previous symptom being absent and not affecting daily life when compared to the pre-operational level of discomfort. These data were condensed per complaint category for the purpose of determining an overall percentage of symptom improvement as measured at 2–4 week post surgical follow-up and final post-operational examination, which averaged 37 weeks.

Both groups demonstrated significant improvement in sinus complaints at the first post-surgical visit (Table 3). 92.9% of patients who underwent BCS and 64.3% of patients who underwent

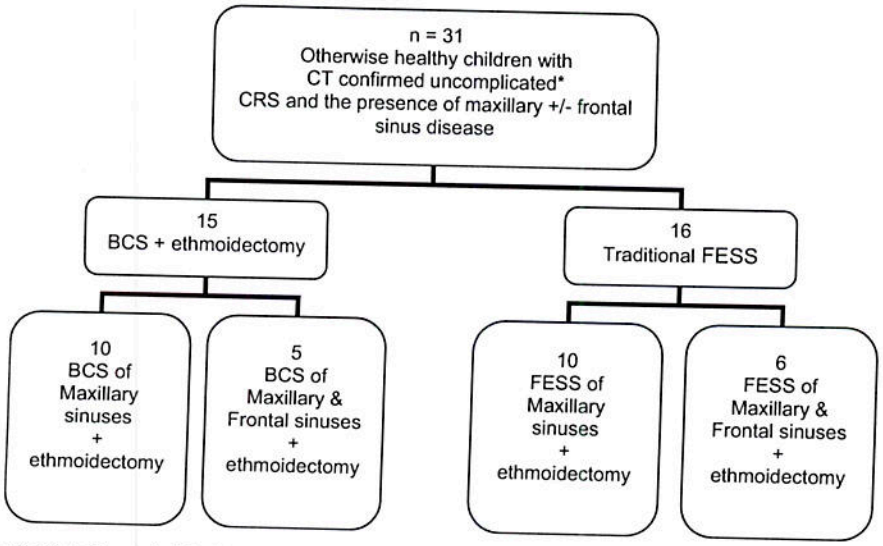


**Fig. 1.** Breakdown of patients' treated with either BCS + ethmoidectomy or traditional FESS and associated paranasal sinuses that were addressed.

**Table 2**
Number of patients reporting an individual symptom being present pre-surgery and at final post surgical visit.

| Individual symptoms | Procedure | Total symptoms | |
|---|---|---|---|
| | | Pre-surgery | Final post-surgical |
| Facial pain | FESS | 7 | 1[a] |
| | Balloon | 7 | 2 |
| Sinus congestion | FESS | 8 | 5[a] |
| | Balloon | 11 | 3 |
| Post nasal drip | FESS | 9 | 4 |
| | Balloon | 9 | 1 |
| Rhinorrhea | FESS | 10 | 3 |
| | Balloon | 13 | 6[a] |
| Headaches | FESS | 10 | 2 |
| | Balloon | 7 | 4 |
| Low grade fever | FESS | 2 | 0 |
| | Balloon | 0 | 0 |

[a] Three children had new complaints at final post-surgical visit: 1 BCS patient complained of increased rhinorrhea, 1 FESS patient complained of new onset facial pain and 1 FESS patient complained of new onset congestion.

traditional FESS demonstrated a reduction of symptoms at the 2–4 week postoperative follow-up. Analysis of this period also revealed a statistically significant improvement of sinus congestion with BCS treatment ($p = 0.01$) when compared to traditional FESS at the 2–4 week post-op assessment (Table 3). This is possibly due to the limited sinus debris seen in BCS post-operatively.

Further long-term statistical analysis revealed that 62.5% of those who underwent traditional FESS and 80.0% of those who submitted to BCS with ethmoidectomy experienced significant improvements in their sinus complaints post-operatively at an average of 37 weeks. When evaluating antibiotic use, at their final visit, 73.3% of patients who underwent BCS and 37.5% who underwent traditional FESS reported no further antibiotic use for sinus infections after initial post-surgical follow-up (Table 3). Children that underwent BCS reported significant improvement of congestion at their final post-surgical visit when compared to FESS ($p = 0.05$). Patients with headaches demonstrated a significant improvement after undergoing FESS ($p = 0.05$).

The overall outcomes of the two groups are illustrated in Fig. 2a and b. Five patients who underwent traditional FESS and 6 BCS patients had total improvement of sinus complaints. BCS and FESS had 6 and 5 patients respectively who reported the absence of at least one pre-operative symptom at last visit. However, 2 of the BCS and 4 of the FESS patients had no change in symptomatology. One patient from the BCS group and two from the FESS group actually had worsening and the addition of new symptoms at the final post surgical visit. One patient who originally underwent BCS required further sinus surgery revision using traditional techniques. No complications were recorded in this study population as a whole.

## 4. Discussion

When maximal medical therapy for pediatric CRS fails, surgical intervention becomes the last option to relieve sinus symptoms [13]. In pediatric otolaryngology, the two most common procedures in the treatment of CRS are adenoidectomy and FESS [14]. FESS has been shown to be effective in the treatment of 80–90% of children with CRS with a major complication rate as low as 0.6% [15]. BCS is another procedure in the armamentarium of the pediatric sinus surgeon using less traumatic minimally invasive techniques.

**Table 3**
Number and percentages of patients in their respective group reporting improvement of sinus symptoms and reporting overall success of sinus surgery at 2–4 weeks post-operatively (post-surgery: FESS $n = 14$ and balloon $n = 16$) and >16 weeks (avg 37 weeks) post-operatively (final post-surgical: FESS $n = 16$ and balloon $n = 15$).

| | % improvement | | $\chi^2$ |
|---|---|---|---|
| | FESS | Balloon | |
| **Symptom total** | | | |
| Post-surgery | 9 (64.3%) | 13 (92.9%) | 3.39* |
| Final post-surgical | 10 (62.5%) | 12 (80.0%) | 1.15 |
| **Individual symptoms** | | | |
| *Facial pain* | | | |
| Post-surgery | 7 (50.0%) | 3 (21.4%) | 2.49† |
| Final post-surgical | 7 (43.8%) | 5 (33.3%) | 0.35 |
| *Sinus congestion* | | | |
| Post-surgery | 2 (14.3%) | 8 (57.1%) | 5.60** |
| Final post-surgical | 4 (25.0%) | 8 (53.3%) | 2.62* |
| *Post nasal drip* | | | |
| Post-surgery | 5 (35.7%) | 9 (64.3%) | 2.29† |
| Final post-surgical | 5 (31.3%) | 8 (53.3%) | 1.55 |
| *Rhinorrhea* | | | |
| Post-surgery | 6 (42.9%) | 7 (50.0%) | 0.14 |
| Final post-surgical | 7 (43.8%) | 8 (53.3%) | 0.29 |
| *Headaches* | | | |
| Post-surgery | 6 (42.9%) | 3 (21.4%) | 1.47 |
| Final post-surgical | 8 (50.0%) | 3 (20.0%) | 3.04* |
| *Low grade fever* | | | |
| Post-surgery | 2 (14.3%) | 0 (0.0%) | 2.01† |
| Final post-surgical | 2 (12.5%) | 0 (0.0%) | 1.89† |
| *Antibiotic use* | | | |
| Post-surgery | 7 (50.0%) | 10 (71.4%) | 1.35 |
| Final post-surgical | 6 (37.5%) | 11 (73.3%) | 4.01* |
| *Allergy medication use* | | | |
| Post-surgery | 4 (28.6%) | 5 (35.7%) | 0.16 |
| Final post-surgical | 3 (18.8%) | 5 (33.3%) | 0.86 |
| *Nasal steroid spray use* | | | |
| Post-surgery | 2 (14.3%) | 3 (21.4%) | 0.24 |
| Final post-surgical | 2 (12.5%) | 2 (13.3%) | 0.01 |

One-tail tests.
† $p < 0.10$.
* $p < 0.05$.
** $p < 0.01$.

The primary objective of both traditional FESS and BCS is to restore paranasal sinus function through the re-establishment of physiologic patterns of ventilation and mucocilliary clearance [16]. In traditional FESS, this is achieved by removing diseased mucosa and bone while preserving normal tissue and opening natural sinus ostia [16]. The belief that osteitis, reactive inflammation and biofilms matrices are primary contributors to the disruption of normal sinus function is what currently makes traditional FESS the primary surgical option for CRS in the adult population [17]. Surgical removal of diseased tissues involving the osteomeatal complex, sinus ostia, uncinate, and all proximal anatomical obstructions, should improve mucocilliary clearance and aeration, enhance the delivery of topical medications, and decrease recurring sinus disease [17–20].

With BCS, restoration of paranasal sinus function is achieved primarily through further tissue preservation and less traumatic sinus ostia expansion. Recent studies have demonstrated that nitric oxide levels, which aid in both mucocilliary transport and inhibition of bacterial proliferation, are higher in maxillary sinuses pre traditional FESS maxillary antrostomy and uncinectomy [21]. In our study, 73.3% of patients who underwent BCS reported a decrease in antibiotic use versus 37.5% in those who underwent FESS. This may in part be due to the antimicrobial affects of retained maxillary sinuses NO levels, as well as, the decreased obliteration of natural sinus tissue in the children investigated.

A recent American Society of Pediatric Otolaryngology (ASPO) survey reported that 55% of pediatric otolaryngologists perform

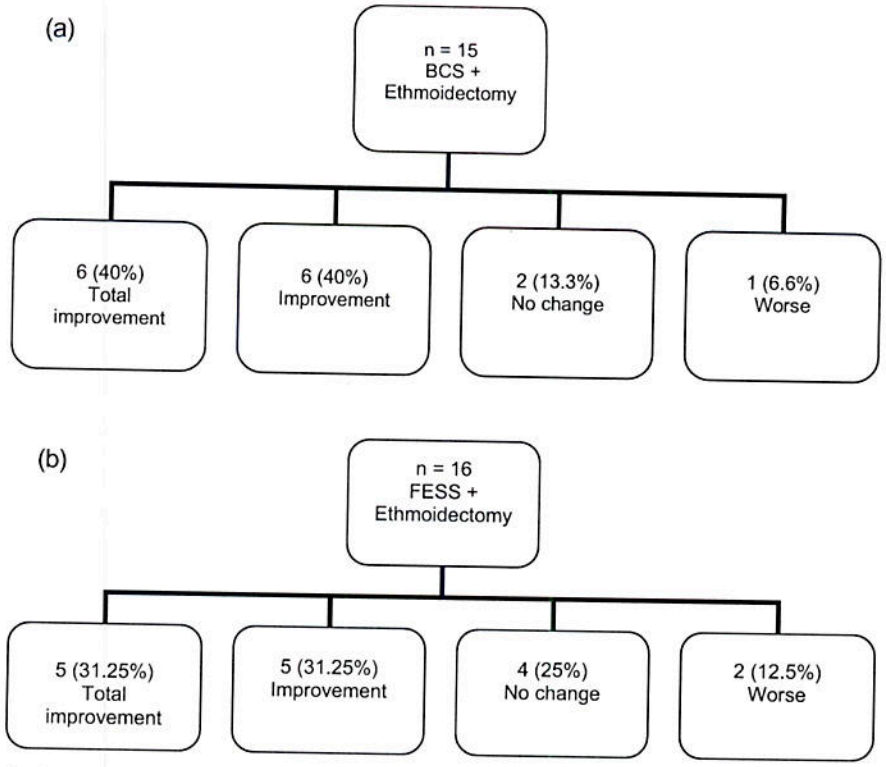


**Fig. 2.** (a) Overall percentage of patients who underwent *BCS with ethmoidectomy* reporting the absence of all previous symptoms (total improvement), absence of at least one pre-operative complaint (improvement), presence of same pre-operative complaint (no change) or presence of new sinus symptoms (worse) at >16 week post-operative visit. (b) Patients who underwent *FESS* reporting the absence of all previous symptoms (total improvement), absence of at least one pre-operative complaint (improvement), presence of same pre-operative complaint (no change) or presence of new sinus symptoms (worse) at >16 week post-operative visit.

adenoidectomy as a primary surgery to treat refractory CRS [22]. Of these practitioners, 81% performed subsequent FESS variant procedures at a later date to further treat refractory CRS [22]. It has recently been demonstrated that BCS is not only safe in the pediatric population but is possibly more effective than adenoidectomy alone in treating most children with CRS [3,17].

In the pediatric population, there is limited empirical data demonstrating clear advantages associated with surgical options to preserve sinus anatomy. A recent adult population study reported that at 24 weeks, 80% of patients who underwent BCS alone and 88% who underwent BCS with ethmoidectomy reported improvement of sinusitis symptoms [23]. Results of our current investigation largely corroborate previously published findings, in that 80.0% of those children who underwent BCS with ethmoidectomy and 62.5% of those treated with traditional FESS experienced improvement of at least one symptom at an average of 37 weeks post-operatively (Fig. 2a and b). Complication rates following BCS have been reported to be lower than those secondary to FESS [3,9]. It has been theorized that BCS reduces the potential for complications like CSF leaks, meningitis, frontal recess stenosis, nasolacrimal duct laceration, epiphora, and orbital hematoma due to its preservation of sinus anatomy and reduction of collateral damage to surrounding tissues during the procedure [14].

The current study is the first to compare BCS with ethmoidectomy to traditional FESS in children with CRS. Pre-operatively both groups were markedly similar, had statistical similarity in diagnosed disease and underwent bilateral surgical treatments of their sinuses (Table 1). Only 2 patients from the FESS group complained of worsening symptoms, and no complications were recorded amongst either group (Fig. 2b). This further demonstrated the safety, feasibility and effectiveness of both BCS and traditional FESS when surgically treating pediatric CRS.

Traditional FESS and BCS with ethmoidectomy achieved similar levels of sinus symptom relief. Unfortunately there were limitations to this study. As a result of the strict inclusion criteria adopted for the current study, the statistical power was inherently low with 31 subjects. The nature of the sample pool was equally confining inasmuch as children seldom undergo sinus surgery for CRS, and it is uncommon for them to be devoid of any other illness that may be contributing to their sinus complaints. Additionally, the data pool was based largely on subjective impressions of symptom improvements. Also, due to the retrospective nature of the study, effectiveness was not evaluated with validated assessments tools such as the SNOT-21. Rather the presence or absence of symptoms described in validated tools such as the SN-5, SNOT-21 and the adult sinusitis clinical practice guidelines were investigated.

A double-blinded chart review process was used to minimize examiner bias of recorded data, and very strict inclusion criteria was followed to ensure homogeneity of the compared subject populations. Also, all patients had the diagnosis of sinus disease confirmed with pre-operative sinus CT-scans and detailed medication use was followed throughout the study. To the authors knowledge the results reported represent the first side-by-side comparison of FESS and BCS procedures for CRS in children.

Surgical intervention for chronic rhinosinusitis is a relatively controversial treatment option in the pediatric population and is only utilized as a last resort to failed medical therapy and in many children previous adenoidectomy. Balloon catheter sinuplasty is a comparatively new treatment option for pediatric CRS when compared to traditional FESS. Further studies are needed to examine its effectiveness and indications for use in this specific population. In this particular study, BCS and its tissue preservation techniques yielded symptom relief and reduced antibiotic dependence in our study population of children with maxillary and

frontal disease who were refractory to conservative therapy and were otherwise free of other ailments. In our institution, as well as others, it has been noted that BCS has a high intraoperative failure rate in hypoplastic sinuses and is far less effective in treating patients with mucociliary diseases like Kartagener's syndrome. For these specific types of patients, more aggressive endoscopic sinus surgery techniques may be required. Overall, prospective studies with a greater number of subjects and more controls are needed to assess BCS as an adjunctive treatment or replacement for FESS in children suffering from CRS.

## 5. Conclusion

Balloon catheter sinuplasty with ethmoidectomy and traditional functional endoscopic surgery are both safe and effective treatment options for otherwise healthy children suffering from uncomplicated CRS who do not respond favorably to pharmacological management. Our results demonstrated, a significant overall decrease in sinus symptoms for both traditional FESS and BCS with ethmoidectomy. There were no complications or adverse events recorded in either group intraoperatively or postoperatively. Larger prospective studies with long term data are needed to determine who will benefit the most from these procedures, and to examine if BCS alone or in combination with ethmoidectomy provides a lasting resolution of sinus complaints, with less morbidity in pediatric CRS when compared to traditional FESS.

## Funding

No relevant financial relationship exists between the authors and procedures or products used in this study.

## Conflict of interest

None declared.

## Acknowledgments

Lisa Chiodo Ph.D.: affiliated with Wayne State University College of Nursing is a statistician and conducted all analyses of data collected. David N. Madgy D.O.: contributing physician, Detroit Medical Center Program Director, and advisor on research collected. Janardhan R. Jagini M.D.: contributing physician and educator. Sweeti Patel D.O.: Otolaryngology Resident at Detroit Medical center, post-graduate year 2. She assisted with development of data collection sheets and aided in compiling all findings in this study.

## References

[1] H.H. Ramadan, Surgical management of chronic sinusitis in children, Laryngoscope 114 (2004) 2103–2109.
[2] C.B. Brown, W.E. Bolger, Safety and feasibility of balloon catheter dilation of the paranasal sinus ostia: a preliminary investigation, Ann. Otol. Rhinol. Laryngol. 115 (2006) 293–299.
[3] H.H. Ramadan, Safety and feasibility of balloon sinuplasty for treatment of chronic rhinosinusitis in children, Ann. Otol. Rhinol. Laryngol. 118 (2009) 161–165.
[4] E.W. William, C.K. Robert, Sinonasal anatomy, function and evaluation, in: B.J. Bailey, J.T. Johnson, S.D. Newlands (Eds.), Head and Neck Surgery—Otolaryngology, 4th ed., Lippincott Williams & Wilkins, Philadelphia, PA, 2006, pp. 307–318.
[5] E. Wald, Subcommittee on Management of Sinusitis and Committee on Quality Improvement, Clinical practice guideline: management of sinusitis. American Academy of Pediatrics, Pediatrics 108 (2001) 798–808.
[6] E. Kim, J. Cutler, Balloon dilatation of the paranasal sinuses: a tool in sinus surgery, Otolaryngol. Clin. North Am. 42 (2009) 847–856.
[7] P.H. Chang, L.A. Lee, C.C. Huang, C.H. Lai, T.J. Lee, Functional endoscopic sinus surgery in children using a limited approach, Arch. Otolaryngol. Head Neck Surg. 130 (2004) 1033–1036.
[8] H.H. Ramadan, A.M. Terrell, Balloon catheter sinuplasty and adenoidectomy in children with chronic rhinosinusitis, Ann. Otol. Rhinol. Laryngol. 119 (2010) 578–582.
[9] C.T. Melroy, The balloon dilating catheter as an instrument in sinus surgery, Otolaryngol. Head Neck Surg. 139 (2008) S23–S26.
[10] R.M. Rosenfeld, Clinical practice guideline: adult sinusitis, Otolaryngol. Head Neck Surg. 137 (2007) S1–S31.
[11] D.J. Kay, R.R. Rosenfeld, Quality of life for children with persistent sinonasal symptoms, Otolaryngol. Head Neck Surg. 128 (1) (2003) 17–26.
[12] J.P. Browne, C. Hopkins, R. Slack, S. Cano, The sino-nasal outcome test (SNOT): can we make it more clinically meaningful? Otolaryngol. Head Neck Surg. 136 (2007) 736–741.
[13] C.A. Buchman, R.F. Yellon, C.D. Bluestone, Alternative to endoscopic sinus surgery in the management of pediatric chronic rhinosinusitis refractory to oral antimicrobial therapy, Otolaryngol. Head Neck Surg. 120 (1999) 219–224.
[14] H.H. Ramadan, J.L. Cost, Adenoidectomy vs. endoscopic sinus surgery for the treatment of pediatric sinusitis, Arch. Otolaryngol. Head Neck Surg. 125 (1999) 1208–1211.
[15] R.L. II Herbert, J.P. III Bent, Meta-analysis of outcomes of pediatric functional endoscopic sinus surgery, Laryngoscope 108 (1998) 796–799.
[16] D. Lai, J.A. Stankiewicz, Primary sinus surgery, in: C.W. Cummings, J.M. Fredrickson, L.A. Harker, et al. (Eds.), 4th ed., Otolaryngology—Head & Neck Surgery, vol. 1:51, St. Louis, MO, Mosby, 2009, pp. 740–757.
[17] J.M. Lee, A.G. Chiu, Role of maximal endoscopic sinus surgery techniques in chronic rhinosinusitis, Orthop. Clin. North Am. 43 (2010) 579–589.
[18] J.T. Lee, D.W. Kennedy, J.N. Palmer, The incidence of concurrent osteitis in patients with chronic rhinosinusitis: a clinicopathological study, Am. J. Rhinol. 135 (3) (2006) 404–408.
[19] P.J. Catalano, E.J. Roffman, Evaluation of middle meatal stenting after minimally invasive sinus techniques (MIST), Otolaryngol. Head Neck Surg. 128 (6) (2003) 875–881.
[20] M.B. St. Martin, C.J. Hitzman, T.S. Wiedman, Deposition of aerosolized particles in the maxillary sinuses before and after endoscopic sinus surgery, Am. J. Rhinol. 21 (2007) 196–197.
[21] R.K. Kirihene, G. Rees, P.J. Wormald, The influence of the size of the maxillary sinus ostium on the nasal and sinus nitric oxide levels, Am. J. Rhinol. 16 (5) (2002) 261–264.
[22] S.E. Sobol, S.S. Daniel, Trends in the management of pediatric chronic sinusitis: survey of The American Society of Pediatric Otolaryngology, Laryngoscope 115 (2005) 78–90.
[23] W.E. Bolger, C.L. Brown, Safety and outcomes of balloon catheter sinusotomy: a multicenter 24-week analysis in 115 patients, Otolaryngol. Head Neck Surg. 137 (2007) 10–20.